Arch Intern Med. 1995 Jun 12;155(11):1225-8.

Perforation of the great vessels during central venous line placement.

Robinson JF[1], Robinson WA, Cohn A, Garg K, Armstrong JD 2nd.

Author information

Abstract

BACKGROUND:

Placement of central venous lines for the administration of a variety of therapies has become common practice. The most severe complication of this procedure is perforation of a large vessel, with bleeding, infusion of fluids into an extravascular site, and death. It is not clear from currently available data how often this occurs, what risk factors are associated, and how this complication can be avoided.

METHODS:

We reviewed the records of all patients who were identified as having perforation of a major vessel during central venous line placement occurring between 1986 and 1993 at the University Hospital, the major teaching facility of the University of Colorado Health Sciences Center, Denver. Data collected included the age and sex of the patient, diagnosis, type of catheter and site of placement, operator means and time to the diagnosis of perforation, and outcome.

RESULTS:

Eleven such complications were identified and 10 of them are reviewed in detail. The overall incidence was less than 1%. Most complications occurred when the right subclavian vein approach was attempted, and they were thought to result from **guidewire kinking** during advancement of a vessel dilator. All medical specialties and levels of training were involved. Four of 10 patients died of immediate or subsequent complications of the perforation.

CONCLUSIONS:

Perforation of a great vessel is an uncommon, but often fatal, complication of central venous line placement. It occurs most often, when using the right subclavian vein approach, from guidewire kinking. Physicians performing this procedure should have formal training in central venous catheterization and be aware of this complication, its presumed cause, diagnosis, and treatment

J Emerg Med. 1999 Jul-Aug;17(4):721-4.

Subclavian central venous catheterization complicated by guidewire looping and entrapment.

Wang HE[1], Sweeney TA.

Author information

Abstract

The placement of central venous catheters is a technically challenging procedure with known risks and complications. We report an attempted left subclavian central venous catheterization that was complicated by looping and entrapment of the guidewire. We hypothesize that this complication occurred because the straight guidewire that was used may have perforated the wall of the vein, allowing the guidewire to loop upon itself. Although catheter looping and knotting are well known potential complications of central venous catheterization, similar complications are rarely reported with guidewires. Clinicians should be aware of these potential complications when performing or teaching central venous catheterization

Korean J Anesthesiol. Mar 2010; 58(3): 296–298.

Published online Mar 29, 2010. doi: 10.4097/kjae.2010.58.3.296

PMCID: PMC2872844

A complication of subclavian venous catheterization: extravascular kinking, knotting, and entrapment of the guidewire -A case report-

Jae Jun Lee,[1] Joo Sung Kim,[1] Woon Seob Jeong,[2] Do Young Kim,[2] Sung Mi Hwang,[1] and So Young Lim[1]

Author information ► Article notes ► Copyright and License information ►

Go to:

Abstract

Various complications of central venous catheterization have been reported, some of which are well-known, while others are described as a sporadic events. We experienced a case of left subclavian venous catheterization complicated by extravascular knotting, kinking, and entrapment of the guidewire and the guidewire was removed surgically. Although minimal resistance was encountered during guidewire insertion, the guidewire was advanced approximately 30 cm. Physicians should be aware of these rare potential complications when a guidewire is advanced if any resistance is encountered.

Keywords: Central venous catheterization, Complications

Central venous catheterization (CVC) is commonly used for diagnosis and treatment, especially in critically ill patients, but CVC can have many severe complications, even for experienced physicians [1]. Mechanical complications of CVC occur in 5% to 19% of patients [2,3] and complications associated with the guidewire include failure to pass, loss in the vessel, kinking, and breakage. There has been no report of kinking, knotting, or entrapment of a guidewire, although intravascular catheter looping and knotting are well-known complications of CVC [4,5]. We present a case of extravascular kinking, knotting, and entrapment of a J-tipped flexible guidewire and successful surgical removal of the wire.

Go to:

Case Report

An 88-year-old woman with a history of hypertension, atrial fibrillation, and unstable angina suddenly developed left-side motor weakness and right-side eyeball deviation.

She was admitted to a district hospital for evaluation and management. Her diagnosis was right middle cerebral artery (MCA) infarction and she was given tissue plasminogen activator (tPA). Seven days later, she suddenly developed dyspnea and unstable vital signs: blood pressure 80/40 mmHg, heart rate 150 beats/min, respiration 44 breaths/min, body temperature 39.1℃, and O_2 saturation 94%. Under the impression of septic shock, she was intubated and left subclavian venous catheterization was attempted because of the need for continued fluid management. Lidocaine was injected at the entry site in the left infrasubclavian area. Then, the left subclavian vein was identified after several attempts using an infraclavicular approach. A Seldinger-type central venous catheter set was used (Two-Lumen Central Venous Catheterization Set with Blue FlexTip, ARROW, USA). The guidewire was passed through the introducer needle, which had been placed with venous return. Minimal resistance was encountered during guidewire insertion, and the guidewire was advanced approximately 30 cm. At that point, the guidewire could be advanced no further and subsequent attempts to withdraw the guidewire were failed despite moderate force. A chest X-ray showed that the guidewire was knotted and kinked and the patient was transferred to our hospital for surgical exploration.

After admission to our hospital, a portable chest X-ray and subclavian venogram were performed for further evaluation. The X-ray revealed that the guidewire was knotted and kinked in the area of the middle third of the left clavicle and that part of it had folded back on itself completely and entered the mediastinum (Fig. 1). The subclavian venogram revealed that the guidewire had not perforated the subclavian vein and was knotted, kinked, and extended extravascularly. The subclavian vein was intact (Fig. 2).

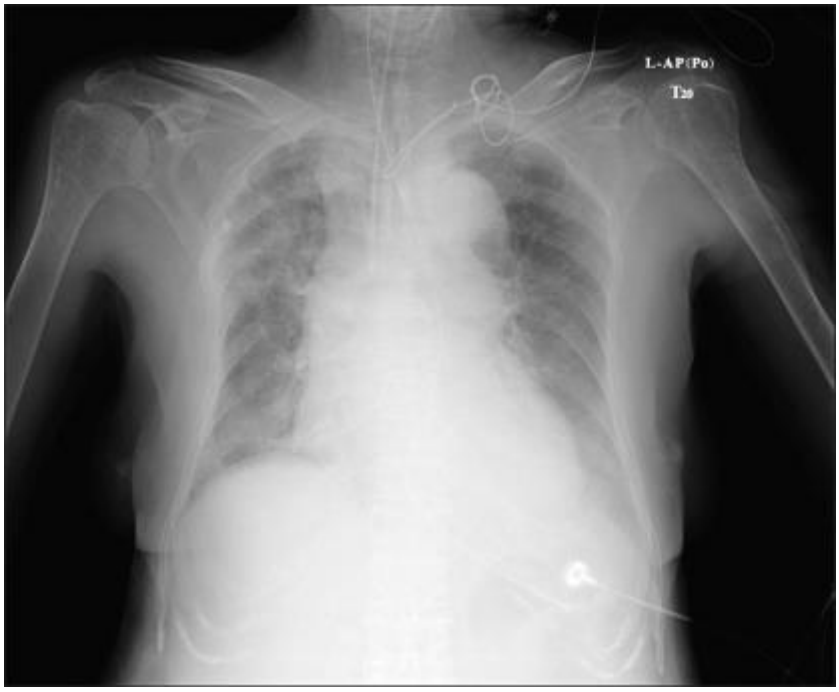

Fig. 1

Chest X-ray showing the knotted, kinked, and entrapped guidewire.

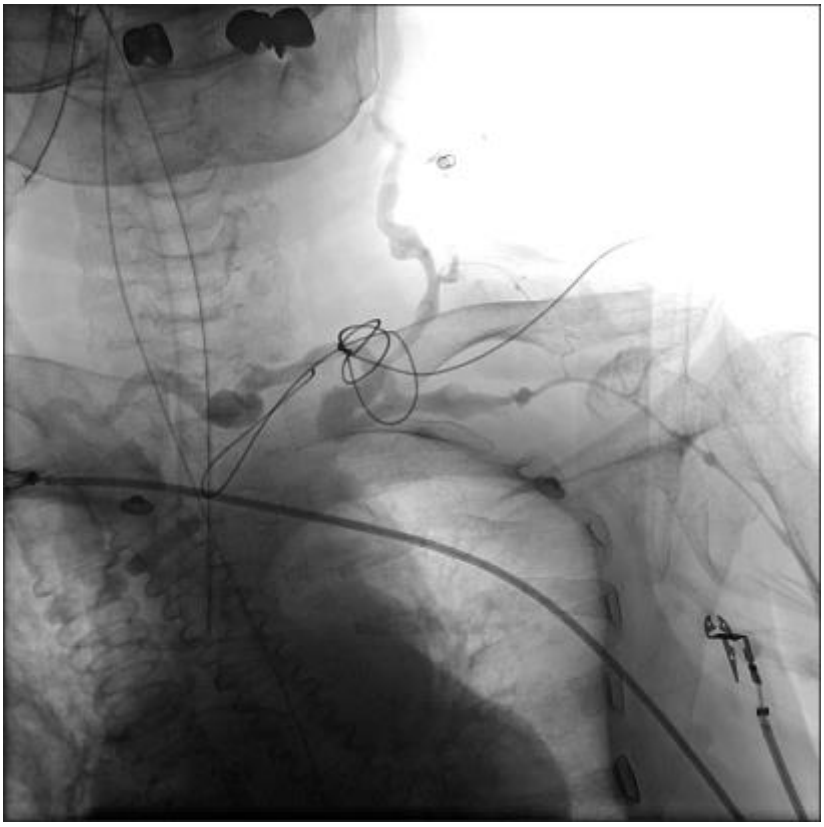

Fig. 2

Subclavian venogram showing the intact left subclavian vein.

Following discussion with orthopedic and chest surgeons, surgical exploration under general anesthesia was decided. In the operating room, the patient's initial vital signs were blood pressure 100/50 mmHg, heart rate 134 beats/min, respiration 25 breaths/min, and O_2 saturation 96%. Anesthesia was induced with 8 mg of etomidate and 40 mg of rocuronium. Although noninvasive blood pressure (NIBP) cuff had been applied on the right arm, an arterial catheter was placed in the left radial artery to continuously check the blood pressure and to promptly detect and monitor the blood pressure changes in case of the damage to the left subclavian artery during operation. And also a femoral venous catheter was applied at the left femoral vein. A 7-cm incision was made just medial to the entry point of the guidewire, parallel to Langer's line. Careful dissection revealed the guidewire just beneath the subclavian vein. The tangled part of the wire was kinked between the sternocleidomastoid muscles and the vessels were not damaged. We cut the wire to untangle it, and pulled out the wire that had entered the mediastinum. The entire guidewire was removed successfully, as confirmed under an image intensifier in the operating field. Postoperatively, the patient was transferred to the surgical intensive care unit, from which she was discharged to a ward the next day without further complications.

Go to:

Discussion

We experienced a case of left subclavian venous catheterization complicated by extravascular knotting, kinking, and entrapment of the guidewire. While some studies

have reported on intravascular knotting or looping of guidewires [6-9], a few cases of extravascular knotting, kinking, and entrapment of guidewires have been reported internationally and we believe that our case is the first domestic report. Wang and Einarsson [10] experienced a similar case, but on surgical cutdown, the wire was discovered to perforate the proximal subclavian vein and knotted behind the clavicle. Their patient had a history of previous subclavian catheterization thus they postulated that damage to the vein from the previous catheterizations predisposed the vessel to perforation by the guidewire. In another similar case, surgical cutdown revealed that the wire had passed through a nearly occluded subclavian vein and into the anterior scalene muscle, where fibrous tissue redirected the wire upward and into a loop [11]. That patient also had a history of five previous subclavian catheterizations.

In our case, the patient had no history of subclavian catheterization and surgical exploration which means that the vessels were not perforated or damaged. The guidewire was located just beneath the subclavian vein and the tangled part of the wire was kinked between the sternocleidomastoid muscles. Furthermore, the first 12 cm of the guidewire from the J-tip was doubled back on itself and extended 6 cm into the mediastinum; no damage occurred to the J-tip.

From these facts, we inferred that the guidewire was initially inserted extravascularly, although the introducer needle had been placed with venous return. The intact subclavian vein and venogram findings supported this supposition. When the J-tip guidewire was inserted into the extravascular connective tissue area, it had folded into a U-shape, which then folded completely upon itself into an I-shape. Finally, this I-shaped wire passed through the connective tissues between the vessel and muscle into the mediastinum, while the rest of the wire, which was under continuous force, became kinked, knotted, and entrapped in the middle clavicular area. This likely resulted from the connective tissue around the subclavian vein and attachment of the vein to the surrounding structures [12]. The loose connective tissues of old age may also have been a contributing factor. Anatomically, the path of the subclavian vein is not straight, as it loops over the first rib to descend into the superior mediastinum. Furthermore, a bottleneck exists between the clavicle and first rib, which can impede the anterograde threading of the wire and might contribute to looping and knotting [6].

In our case, minimal resistance was encountered during guidewire insertion. Consequently, we emphasize that a guidewire should not be advanced if any resistance is encountered, as originally pointed out by Seldinger [13]. Guidewires are not very rigid structures and if any force is applied they are likely to kink, moreover, further application of force after kinking might result in knot formation [6]. If we pull out the knotted guidewire back, the guidewire might be entrapped. To avoid these complications, if there is any resistance, guidewire should not be advanced and resistance encountered during insertion of the guidewire, it is necessary to check the chest x-ray to determine the position of the guidewire instead of pulling it back. Our case shows the consequences of inserting a guidewire despite of minimal resistance and pulling it backward when the guidewire is not advancing.

In conclusion, CVC is commonly practiced by anesthesiologists, surgeons, and emergency room physicians. We present a rare complication of subclavian venous catheterization. Initially, the guidewire was passed through extravascular connective tissue and then the wire became knotted, kinked, and entrapped extravascularly.

Physicians should be aware of these rare potential complications when a guidewire is advanced if any resistance is encountered.

Go to:

References

1. Boon JM, van Schoor AN, Abrahams PH, Meiring JH, Welch T, Shanahan D. Central venous catheterization-an anatomical review of a clinical skill-part 1: subclavian vein via the infraclavicular approach. Clin Anat. 2007;20:602–611. [PubMed]

2. Merrer J, De Jonghe B, Golliot F, Lefrant JY, Raffy B, Barre E, et al. French Catheter Study Group in Intensive Care. Complications of femoral and subclavian venous catheterization in critically ill patients: a randomized controlled trial. JAMA. 2001;286:700–707. [PubMed]

3. Mansfield PF, Hohn DC, Fornage BD, Gregurich MA, Ota D. Complications and failures of subclavian-vein catheterization. N Engl J Med. 1994;331:1735–1738. [PubMed]

4. Malatinsky J, Kadlic T, Majek M, Samei M. Misplacement and loop formation of central venous catheters. Acta Anaesthesiol Scand. 1976;20:237–247. [PubMed]

5. Nicholas F, Fenig J, Richter RM. Knotting of subclavian central venous catheter. JAMA. 1970;214:373–374. [PubMed]

6. Khan KZ, Graham D, Ermenyi A, Pillay WR. Case report: managing a knotted Seldinger wire in the subclavian vein during central venous cannulation. Can J Anesth. 2007;54:375–379. [PubMed]

7. Leigh TR, Baker LR, Cattell WR. Internal knotting of a guidewire: a complication of subclavian vein cannulation. Nephron. 1987;46:210. [PubMed]

8. Koundouris C, Tornaris G, Charopoulos I, Vounasis A, Solomou G. Subclavian vein flexible guidewire knotting. A potential serious complication in hemodialysis patients. Chirurgia (Bucur) 2004;99:61–64. [PubMed]

9. Kim SY, Jang YH. J-guide wire knotting during the central venous catheterization. Korean J Anesthesiol. 2003;44:725–728.

10. Wang LP, Einarsson E. A complication of subclavian vein catheterisation. Extravascular knotting of a guidewire. Acta Anaesthesiol Scand. 1987;31:187–188. [PubMed]

11. Kjeldsen L. Transvenous misplacement and loop formation of spring guide wire. Anaesthesia. 1987;42:216–217. [PubMed]

12. Mothers LH, Smith DW, Frankel L. Anatomic considerations in placement of central venous catheters. Clin Anat. 1992;5:89–106.

13. Seldinger SI. Catheter replacement of the needle in percutaneous arteriography: a new technique. Acta Radiol. 1953;39:368–376. [PubMed]

Fracture of J-tipped guidewire during central venous catheterization and its successful removal under fluoroscopic guidance -A case report-

Korean J Anesthesiol. Nov 2012; 63(5): 457–460.
Published online Nov 16, 2012. doi: 10.4097/kjae.2012.63.5.457

Sun Kyung Park, In-Kyong Yi, Jae-Ho Lee, Dae-Hee Kim, and Sook Young Lee

Author information ► Article notes ► Copyright and License information ►

Go to:

Abstract

Central venous catheterization by Seldinger's technique uses a guidewire which may cause complications such as kinking, knotting and fracture. Fractured guidewire may lead to severe outcomes such as embolization, and removal of it may also cause problems such as vessel damage. We experienced a case of right internal jugular venous catheterization complicated by guidewire fracture entrapped in the central venous catheter, and its successful removal under fluoroscopic guidance using snare-loop. The patient recovered without any complications. When resistance is felt during insertion or withdrawal of the guidewire, force should not be applied to the guidewire and care should also be exercised when passing the tissue dilator over the guidewire. Clinicians should be aware of this rare complication and snare-loop technique could be considered as one of the methods for removal of the fractured guidewire.

Keywords: Central venous catheterization, Fracture, Guide wire

Central venous catheters (CVCs) are used for the administration of drugs, hemodialysis/hemofiltration, hemodynamic monitoring and transvenous cardiac pacing. Large bore CVCs are used for the rapid infusion of resuscitation fluids [1]. Central venous catheterization is commonly performed by the Seldinger technique, which mandates the use of a guidewire [2,3]. Guidewire-associated complications include kinking, knotting, looping, breakage, and fracture [4-11]. Broken or fractured fragments of guidewire can lead to severe outcomes such as embolization or even cardiac arrest [10,11]. Removal of guidewire fragments may be performed using a snare-loop catheter through the femoral vein [12,13]. There have only been a few rare reports of fracture and entrapment of CVC guidewires. We report a case of fractured guidewire that was entrapped in the CVC and its successful removal under fluoroscopic guidance using a snare-loop catheter.

Go to:

Case Report

A 63 year-old female patient was admitted to our hospital for laparoscopic splenectomy. Her diagnosis was ovarian cancer with splenic metastasis and there were no specific findings in the laboratory data and physical examination. At admission, blood pressure and heart rate were 100/63 mmHg and 74 beats/min, respectively. Anesthesia was induced with thiopental sodium (4-5 mg/kg) and was maintained with sevoflurane 2-2.5 vol%. The patients were given rocuronium (40 mg) to facilitate tracheal intubation. Ventilation was mechanically controlled with O_2/air mixture (fractional inspired oxygen [F_{iO2}] = 0.5) and adjusted to keep an end-tidal concentration of CO_2 between 35 and 40 mmHg throughout the operation.

After the induction of anesthesia, central venous catheterization through the right internal jugular vein was attempted with two 14G lumen indwelling catheter sets (Spectrum® Central venous Catheter Set, Cook Medical, USA). The enclosed introducer steel needle was used for puncture of the right internal jugular vein and free aspiration of blood was confirmed. The first attempt to insert the J-shaped guidewire failed with resistance. While lefting the introducer needle and guidewire, a more experienced clinician tried a second attempt and the guidewire passed through the venipuncture needle with resistance at the final step. The guidewire advanced approximately 19 cm beyond the needle tip. The tissue dilator was inserted over the guidewire without any problems. After removing the dilator, a double lumen catheter was inserted over the guidewire. More resistance was felt while attempting to withdraw the guidewire, so the guidewire was pulled out with force. The removed guidewire was observed to be damaged. The core wire was cut at the middle of the guidewire, and its surrounding cover coils detached and extended from the core wire (Fig. 1). It was not clear whether the J-shaped end was lost or not because the outer cover coil was extended long (Fig. 1). To confirm, chest x-ray was taken, which revealed that the guidewire including the J-shaped tip was entrapped in the CVC (Fig. 2). We suspected fracture of the guidewire and a radiologist was called for correct diagnosis as well as to remove the guidewire. To remove the fractured fragment, a snare-loop catheter 6 Fr. (Multi-Snare® set 30 mm, pfm-prodokte für die Medizin AG, Köln, Germany) with a loop diameter of 30 mm was introduced through the femoral vein with the help of a fluoroscopic intensifier (Series 9800, GE OEC Medical Systems Inc., Cleveland, USA). The catheter passed into the superior vena cava adjacent to the J-shaped tip of the fractured guidewire. The snare was opened and slipped over the tip. The snare was tightened and the tip of the guidewire was withdrawn without difficulty. The removed fractured guidewire revealed a 19 cm length without detaching the outer cover coil. The guidewire curved from 3 cm proximal to the J-shaped tip by snare loop during removal of the guidewire. The total anesthesia and operation time was 295 min and 195 min, respectively. The total time from the start of anesthesia induction to the removal of fragmented guidewire was 60 min. Postoperatively, the patient was transferred to the general ward. The patient was discharged at postoperative days 9 without any complication associated with CVC.

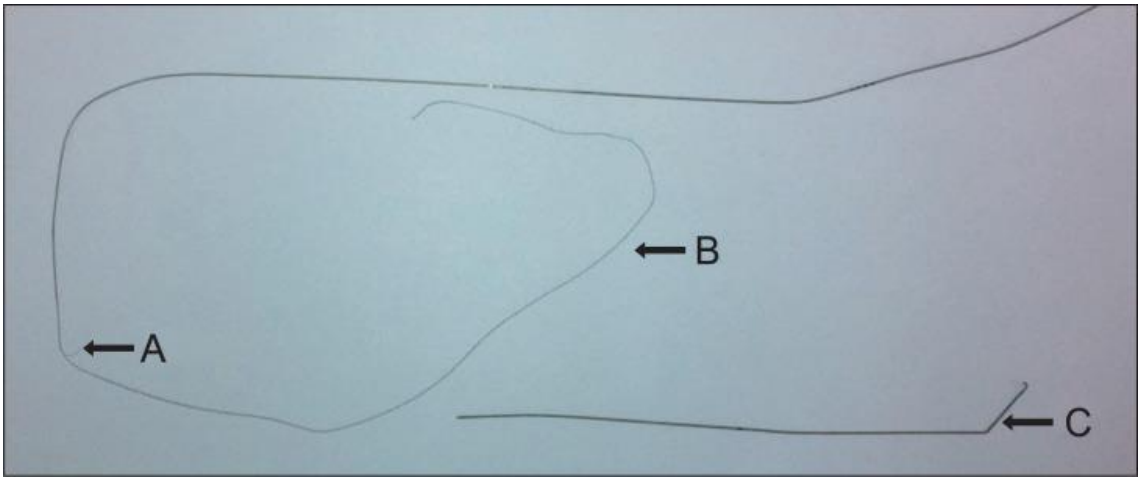

Fig. 1

Image of the fractured guidewire. (A) The cut end of the core wire from the proximal part of the fractured guidewire. (B) The detached and extended outer cover coil of the proximal part of the fractured guidewire. (C) The retrieved part of the guidewire **...**

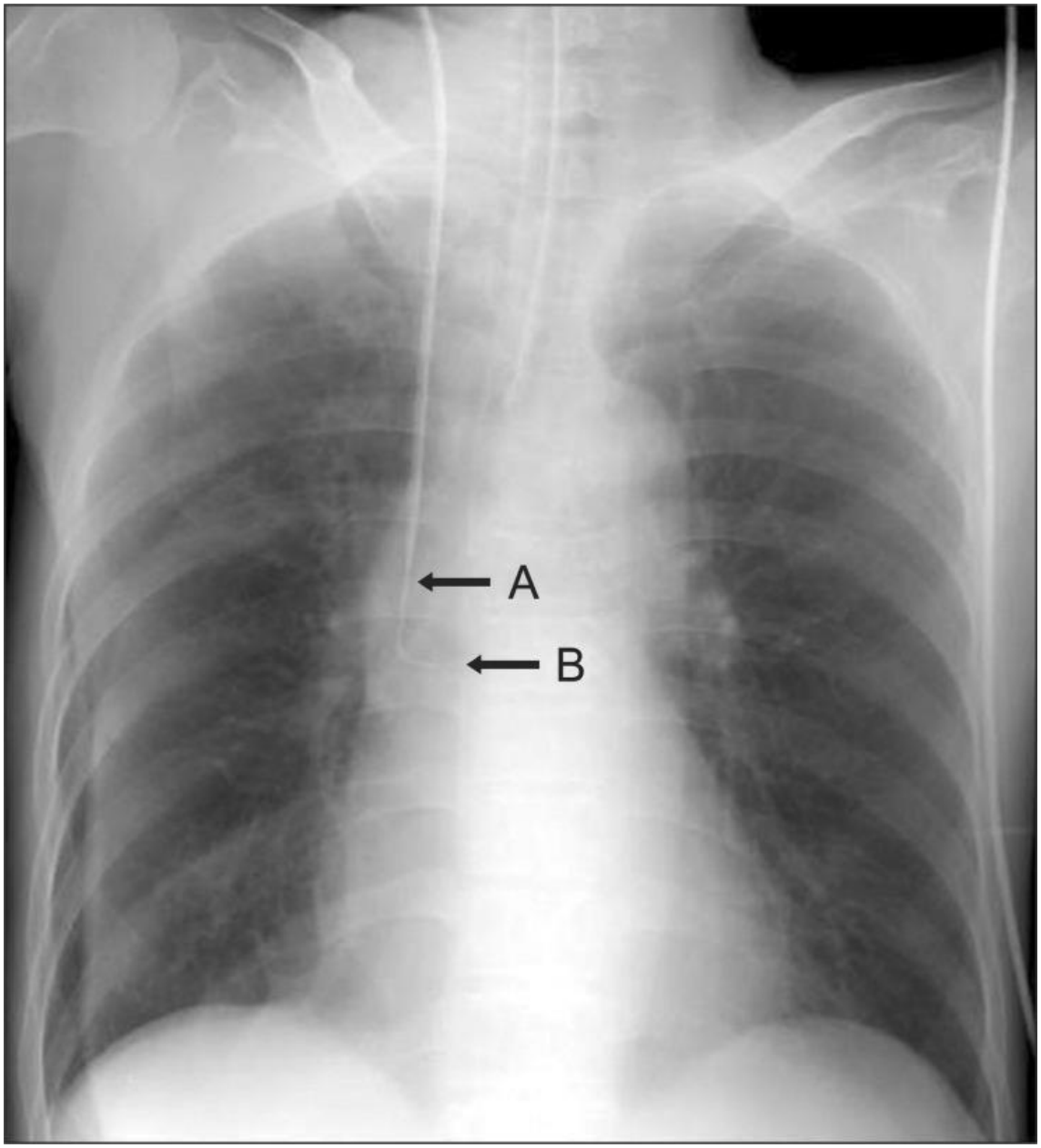

Fig. 2

Chest x-ray showing the fractured guidewire entrapped in the central venous catheter (CVC) located in the superior vena cava. (A) End of CVC. (B) End of fractured guidewire entrapped in the CVC.

Go to:

Discussion

We report a case of fractured J-tipped guidewire being entrapped in the CVC during internal jugular venous catheterization and its successful removal with snare-loop catheter under fluoroscopic guidance.

Central venous catheterization is associated with numerous complications including mechanical, infectious or thrombotic [12]. The reported rate of mechanical

complications such as arterial puncture, air embolism, nerve injury and hemo- or pneumothorax is between 5% and 19% [14,15]. Central venous catheterization is usually carried out by Seldinger's technique using guidewire which may cause complications such as failure to pass, loss in the vessel, kinking, knotting, breakage and fracture [4-11].

Safe use of guidewires for central venous access requires care in handling and understanding of the physical characteristics [6,8]. The guidewire consists of an inner single filament core wire and a surrounding coiled wire cover. Apart from the two ends of the guidewire, there is no further point of attachment between the core and the outer wire. Hence, any damage to the guidewire on its stem may lead to unwinding of the whole outer spiral. In our case, the outer coiled wire of the proximal part of the fractured guidewire was unwound. The J-shaped end results from rounding and flattening of the core which causes structural weakness and may lead to potential breakage [6,8]. In our case, the J-shaped end was damaged 3 cm distal from the tip of the end. However, the etiology of this damage may be the force applied to this part while removing the guidewire with the snare-loop. This could be evidenced by the initial chest radiograph showing an intact J-shaped end of the guidewire which was entrapped in the CVC (Fig. 2).

The removed guidewire (19 cm length) including the J-shaped end was fractured without the outer coil detachment. The proximal part of the fractured guidewire showed a cut core wire with a detached and stretched outer coil from the cut end (Fig. 1). The etiology of this complication could be described as follows. During guidewire insertion, we felt resistance mainly at the final step when the guidewire reached about 19 cm from the puncture needle tip (20 cm from the skin). At this time, initial damage to the guidewire due to the bevel of the accompanying puncture needle could have occurred. Although no problem was encountered while inserting the tissue dilator, secondary damage could be added to the guidewire since the initial damage had already occurred. During the insertion of the catheter with subsequent withdrawal of the guidewire, we also felt more resistance. However, we pulled out the guidewire with force. At this time, the guidewire may have been cut completely and the distal part of the fractured guidewire remained in the CVC. Further pulling of the guidewire may have caused the uncoiling of the outer cover coil of the proximal part of the guidewire. Monaca et al. [8] reported that if breakage occurred only in the inner part of the wire, it could exclude the effect of the needle. In our case, the inner wire and outer covering coil was fractured together and the damage to the guidewire could be from the puncture needle. Tissue dilators could cause complications to the guidewire [6]. In our case, there was no problem during insertion of the dilator. However, there may be damage to the guidewire because the initial damage had already occurred to the guidewire.

Breakage or fracture of the guide wire can cause complications including myocardial perforation, pulmonary embolism, arrhythmias, sepsis, endocarditis and even cardiac arrest [12]. The unpredictability of such complications mandates that immediate removal of foreign bodies be addressed. Techniques for removal of foreign bodies vary and depend on the type of fragment, its location, and the experience of the operator [11]. The most commonly used techniques are snare-loop or basket catheter [11,12]. In our case, the fractured guidewire entrapped in the CVC was removed using a snare-loop catheter (Fig. 3) without any complications.



Fig. 3

Figure showing the J-tipped guidewire and snare-loop catheter. (A) Snare-loop slipped over the guidewire. (B) Tightened guidewire with snare-loop before being withdrawn.

We suggest that no force should be applied during insertion or withdrawal of the guidewire if resistance is felt and care should also be exercised when passing the tissue dilator over the guidewire. Furthermore, the snare-loop technique under fluoroscopic guidance could be considered a safe method for the removal of a fractured guidewire.

Go to:

References

1. Taylor RW, Palagiri AV. Central venous catheterization. Crit Care Med. 2007;35:1390–1396. [PubMed]

2. Seldinger SI. Catheter replacement of the needle in percutaneous arteriography; a new technique. Acta radiol. 1953;39:368–376. [PubMed]

3. Sternbach G. Sven Ivar Seldinger: catheter introduction on a flexible leader. J Emerg Med. 1990;8:635–637. [PubMed]

4. Carpentier JP, Braz da Silva J, Choukroun G. Formation of a knot in a J spiral metallic guide: a complication of the Seldinger method. Cah Anesthesiol. 1991;39:277–278. [PubMed]

5. Shimamoto T, Arai T. Breakage of a Seldinger spring guide wire during percutaneous catheterization of a subclavian vein. Masui. 1997;46:376–378. [PubMed]

6. Khan KZ, Graham D, Ermenyi A, Pillay WR. Case report: managing a knotted Seldinger wire in the subclavian vein during central venous cannulation. Can J Anaesth. 2007;54:375–379. [PubMed]

7. Han HS, Jeon YT, Na HS, Hwang JY, Choi EJ, Kim MH. Successful removal of kinked J-guide wire under fluoroscopic guidance during central venous catheterization -A case report- Korean J Anesthesiol. 2011;60:362–364. [PMC free article] [PubMed]

8. Monaca E, Trojan S, Lynch J, Doehn M, Wappler F. Broken guide wire--a fault of design? Can J Anaesth. 2005;52:801–804. [PubMed]

9. Wang HE, Sweeney TA. Subclavian central vcenous catheterization complicated by guidewire looping and entrapement. J Emerg Med. 1999;17:721–724. [PubMed]

10. Garg R, Ramaiah VK, Chouhan RS. Damaged guidewire by the introducer needle tip while inserting central venous catheter in subclavian vein by supraclavicular approach. Saudi J Anaesth. 2010;4:210–212. [PMC free article] [PubMed]

11. Polos PG, Sahn SA. Complication of central venous catheter insertion: fragmentation of a guidewire with pulmonary artery embolism. Crit Care Med. 1991;19:438–440. [PubMed]

12. Fisher RG, Ferreyro R. Evaluation of current techniques for nonsurgical removal of intravascular iatrogenic foreign bodies. AJR Am J Roentgenol. 1978;130:541–548. [PubMed]

13. Dagdelen S, Yuce M, Caglar N. Percutaneous removal of two intracardiac and pulmonary truncal catheter fragment by using a snare-loop catheter. Int J Cardiol. 2007;116:413–415. [PubMed]

14. Merrer J, De Jonghe B, Golliot F, Lefrant JY, Raffy B, Barre E, et al. French Catheter Study Group in Intensive Care. Complications of femoral and subclavian venous catheterization in critically ill patients: a randomized controlled trial. JAMA. 2001;286:700–707. [PubMed]

15. Mansfield PF, Hohn DC, Fornage BD, Gregurich MA, Ota DM. Complications and failures of subclavian-vein catheterization. N Engl J Med. 1994;331:1735–1738. [PubMed]

J Anaesthesiol Clin Pharmacol. 2014 Apr-Jun; 30(2): 267–269.

doi: 10.4103/0970-9185.130061

PMCID: PMC4009653

Percutaneous retrieval of malpositioned, kinked and unraveled guide wire under fluoroscopic guidance during central venous cannulation

Gopal Krishan Jalwal, Vanitha Rajagopalan, Ashish Bindra, Girija Prasad Rath, Keshav Goyal, Atin Kumar,[1] and Shivanand Gamanagatti[1]

Author information ► Copyright and License information ►

Go to:

Abstract

The placement of central venous catheter using Seldinger's technique, remains a commonly performed procedure with its own risks and benefits. Various complications have been reported with the use of guide wire as well as catheter. We report a unique problem during subclavian vein cannulation due to guidewire malposition which led to its kinking and difficult retrieval requiring removal in fluoroscopy suit. The probable mechanism of guide wire entrapment and possible bedside management of similar problems is described.

Keywords: Central venous cannulation, entrapment, fluroscopy, guide wire, prevention, unraveling

Go to:

Introduction

The placement of central venous catheter using Seldinger's technique, though a commonly performed procedure in the intensive care unit, has its own risks and complications. Various complications have been reported with the use of guide wire as well as catheter. Both malposition and entrapment of guidewire are known to occur during subclavian vein (SCV) cannulation.[1,2] We report a case of SCV cannulation in which guide wire went to ipsilateral internal jugular vein (I/L IJV) and with subsequent passage of dilator it got kinked and directed to superior vena cava (SVC). The attempts at removal of this guidewire caused its unraveling. Though removal of entrapped guidewire in interventional radiology suite has been described as a possible method, kinks remote to entry site and its unraveling made the task difficult. As a result,

combined transfemoral and subclavian route was used for its retrieval. The preventive measures and treatment of similar problems is discussed.

Go to:

Case Report

A 35-year-old, 70 kg, 180 cm, male patient with traumatic cervical spine injury was admitted to our intensive care unit with chief complaints of labored breathing and partial loss of power in all four limbs. After securing the airway with a tracheal tube, central venous cannulation was attempted using 7 F20 cm triple lumen catheter (Certofix, Braun, Germany). Under strict aseptic precautions landmarks were identified and right SCV was located infraclavicular at medial 2/3 and lateral 1/3 of the clavicle using introducer needle in single attempt. After confirming good backflow of the blood, guide wire (50 cm with j-tip), was introduced up to 15 cm mark without any resistance. After that tissue dilator was threaded over the guide wire followed by railroad of triple lumen catheter (up to 13 cm) over it, although the line was inserted in single pass but resistance was encountered during removal of guide wire. Gentle traction was applied several times to remove it but all in vain. Bed side chest roentgenogram revealed the guidewire going through right SCV towards SVC but after its entry it took sharp turn and entered IJV on the same side [Figure 1]. With bed side X-ray as a control we tried to remove the guide wire, pushing it caused the assembly to move inside the right atrium (arrhythmia elicitation) but attempts at removal resulted in decoiling at the site of insertion. This prevented the applied force from being transmitted to the stuck component. Further attempts at removal of the guidewire were deferred and patient was shifted to intervention radiology suite. The attempts at removal of guidewire by passing a tissue dilator to straighten the kinked portion were not met with success, so through percutaneous right transfemoral venous route a vascular snare was used to pull the guide wire out of IJV [Figure 2]. It was followed by successful railroad of long and large bore tissue dilator from the unraveled to the intact segment of guide wire from the insertion site. The incision at site of insertion was then deepened to remove the kinked portion [Figure 3]. Another guidewire was passed through the same dilator followed by insertion of triple lumen catheter. A post-procedural chest radiograph revealed no evidence of hemothorax or pneumothorax.

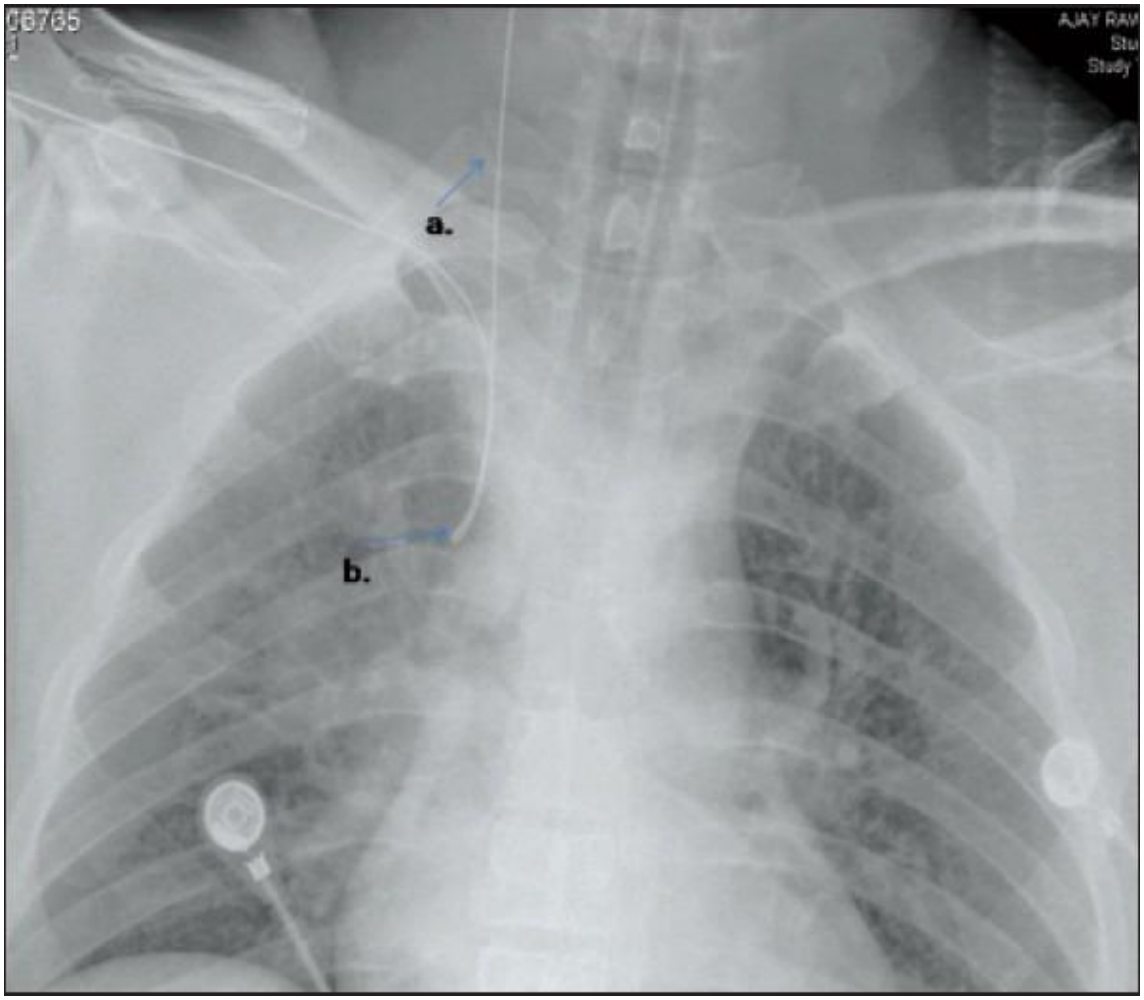

Figure 1

Portable chest X-ray showing looping of the guidewire a. into internal jugular vein b. superior vena cava

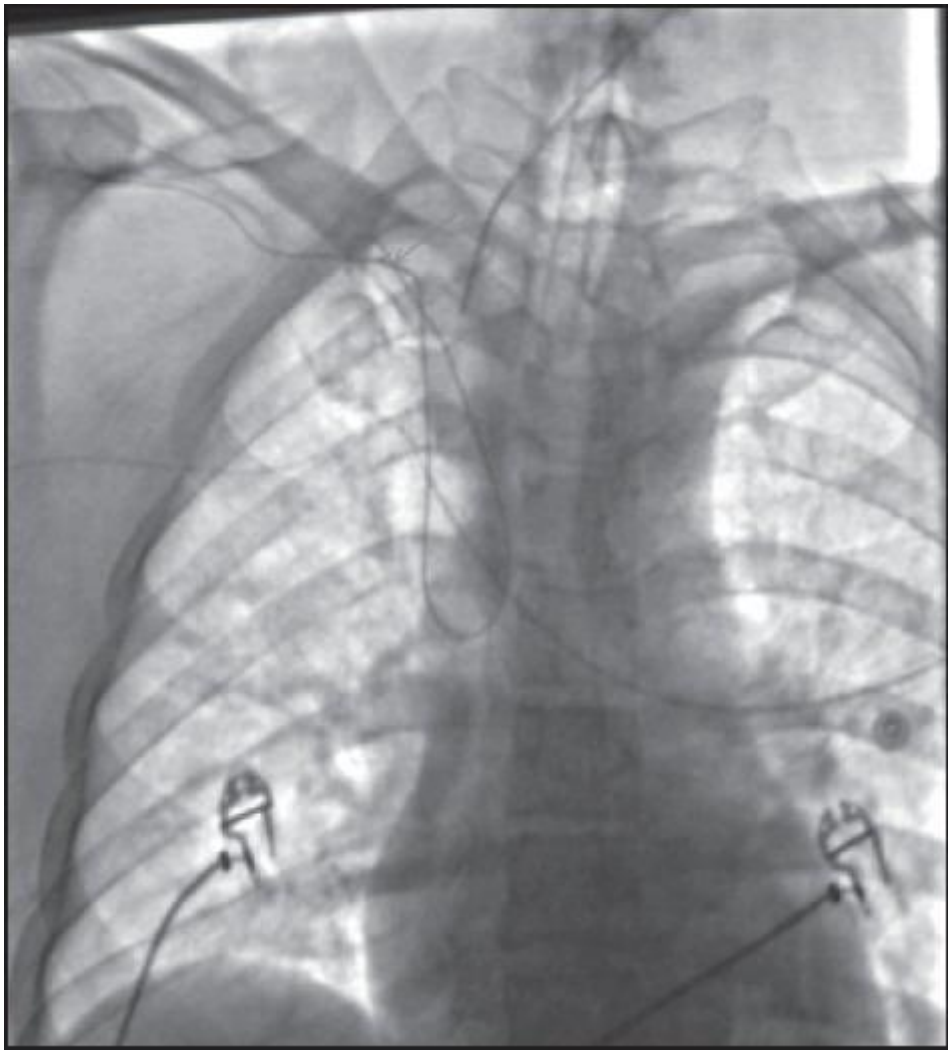

Figure 2

Guidewire dragged from internal jugular in the radiology suit (arrow)



Figure 3

The unraveled guidewire after removal

Go to:

Discussion

We present a case of malpositioning, kinking and unraveling of guidewire during SCV cannulation. It seems that at the time of insertion, the guidewire got malpositioned into I/L IJV and the passage of dilator over it caused it to kink and enter SVC on the same side [Figure 1]. Catheter placement into IJV is the most frequent malposition during cannulation of SCV using infraclavicular approach.[1] In the current case kinking during subsequent passage of dilator was seen which is a rare finding. Various maneuvers like turning the head to ipsilateral (I/P) side, compression of I/P IJV during insertion of the guidewire, keeping the J-tip directed downwards and electrocardiography guidance have been described to prevent it.[3] The described management for removal of entrapped intravascular foreign body include application of slow gentle traction, surgical exploration or maneuvering in interventional radiology.[4] In this case the application of traction resulted in unraveling of guidewire making the situation even more problematic. The guidewire used for central venous cannulation is made up of two parts. There is an inner single filament wire core which is surrounded by spiral covering welded to the core filament at both ends. According the testing guideline available (ISO: 11070) the minimum force at break for the guidewire used in central venous access procedure is 5 Newton, which is pretty less. Depending upon the manufacturer's specifications the weld seams of outer covering at both the ends can withstand a pull strength of 17 N (1.73 Kg) before detaching from its core, whereas in

the middle section guidewire can withstand a stress of up to 290 N. Guidewire made by B Braun, Germany, used in this case can withstand a force of 24 N.[5] We feel that application of firm pressure caused the surrounding coil to unwind (like an overstretched spring); however, the force was insufficient to break the inner filament. This may be the reason why we did not encounter negative consequences like breakage and embolization of the guidewire. Such guidewire related complications can happen either due to manufacture defect or because of faulty technique. We believe that intention to remove a malpositioned and subsequently kinked guidewire caused its unwinding; fortunately the pressure was inadequate to cause breakage of inner filament and subsequent embolization.

Due to less invasive nature percutaneous removal in interventional radiology suite is a preferred method as compared to open surgical removal so we opted for the former. There are case reports in which fluoroscopy was used for removal of kinked guide wire. However, in these reports periclavicular region was the most common site of kink and the passage of dilator to straighten it was key to success.[6] We tried using this route but the unique course and kinking remote to the site of insertion required use of transfemoral loop snare to pull it out of IJV. This was followed by manual pulling of the kinked and broken wire towards the site of insertion and passage of wide bore tissue dilator over it and removal. Intervenational radiology suite proved to be the safe and effective alternative for removal of the badly struck guidewire.

Hence to conclude, caution should be exercised during placement of guidewire. Do not pull guidewire which is suspected to be kinked. Desperate attempts at removal of struck or kinked guidewire may result in loss of mechanical integrity, unraveling and breakage and possible embolization. Do not thread a dilator over a guidewire which is suspected to be kinked for some reason. The use of fluoroscopic control in the form of bedside digital radiograph or intervention suit may help in the determination of condition and position of guidewire and should be preferred over to blind attempts at removal. The withdrawal of a kinked guidewire by means of interventional radiology is the procedure of choice.